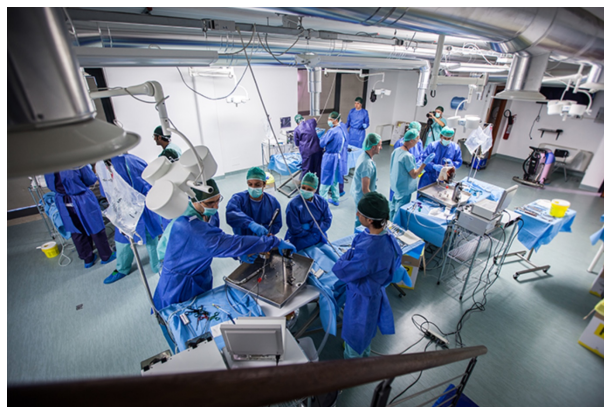

# Resuscitative Thoracotomy and REBOA



Mr Mansoor Khan

MBBS(Lond) PhD FRCS(GenSurg) FEBS(GenSurg) FACS AKC

Consultant Trauma Surgeon

St Mary's Hospital, Paddington, London

Consultant Advisor in General Surgery to Medical Director General Royal Navy



@traumakhan

**Respect** our patients and colleagues | Encourage **innovation** in all that we do | Provide the highest quality **care** | Work together for the **achievement** of outstanding results | Take **pride** in our success

# Disclosure

Views are my own and don't represent the views of any of my affiliated organisations.

Grateful to Dr DuBose and Prytime Medical for resources and slides

No one should die from haemorrhage

# Introduction

- A lot of trauma management can be read about in books
- There is very little Level I evidence in trauma
- I will try and fill in some gaps

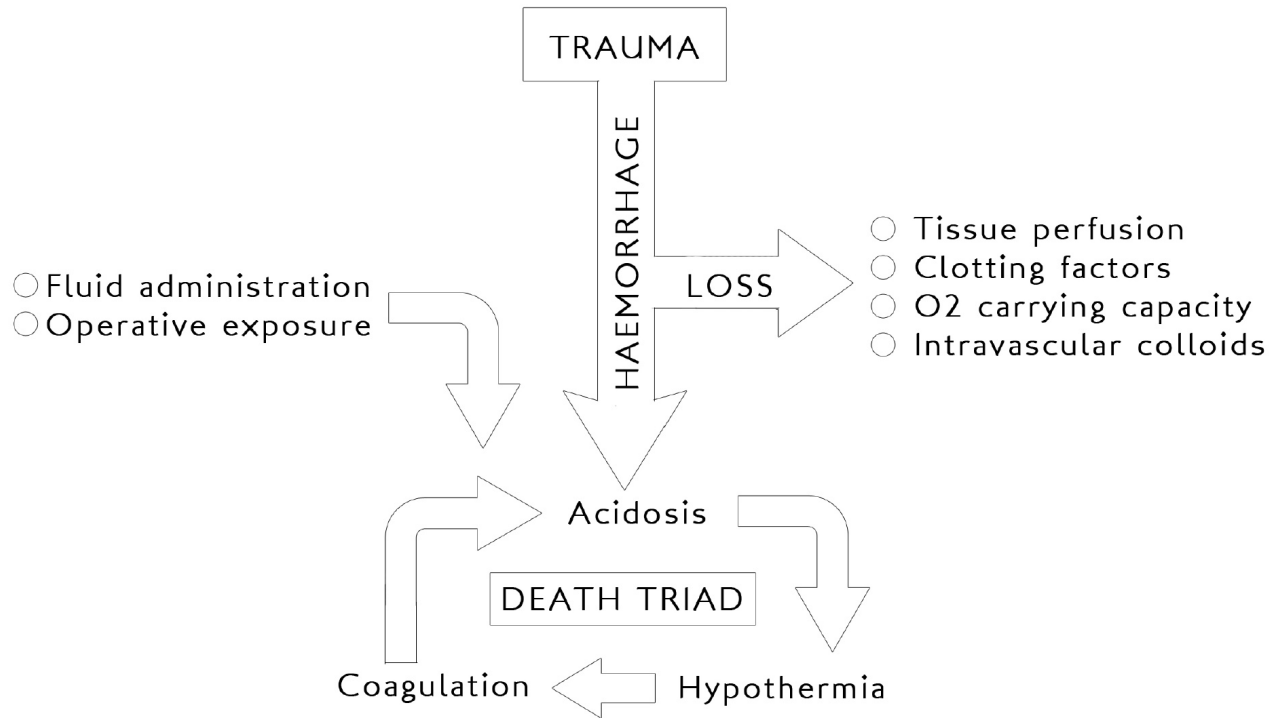


Time is the enemy in traumatic  
haemorrhage

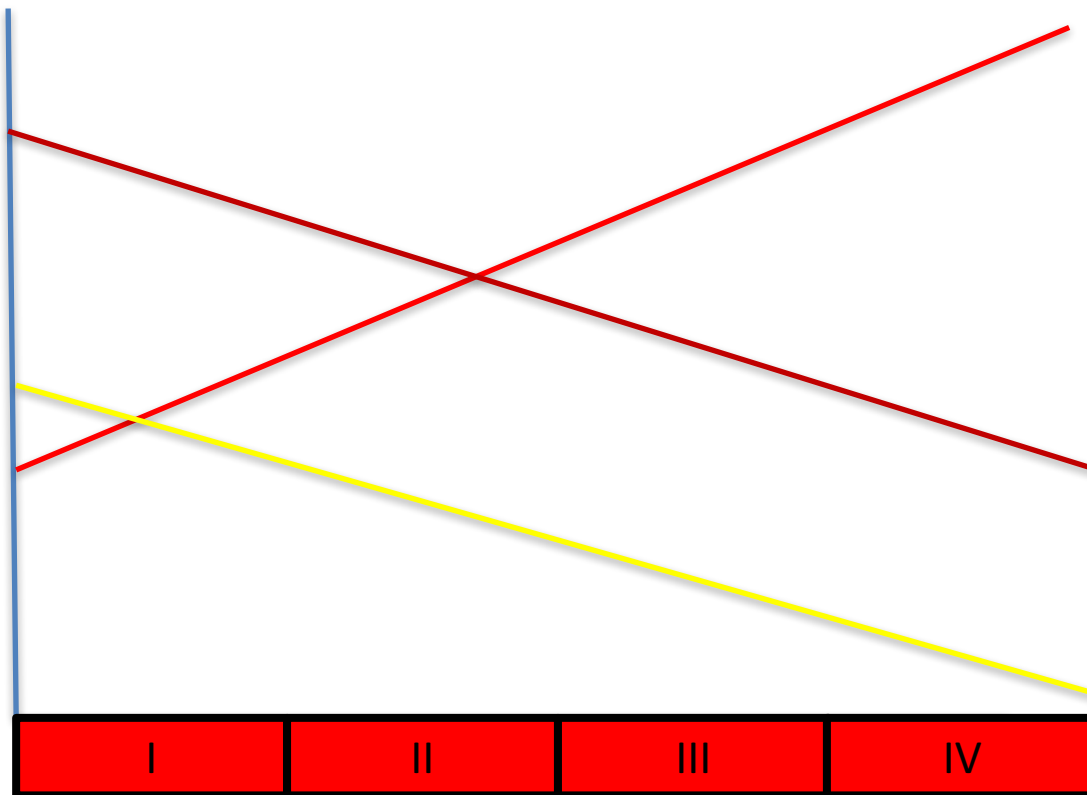
# Damage Control Resuscitation

- Principles of management in adults known for years
- Major Trauma in children is still poorly understood
- No RCTs of DCR in Children!

# Lethal Triad

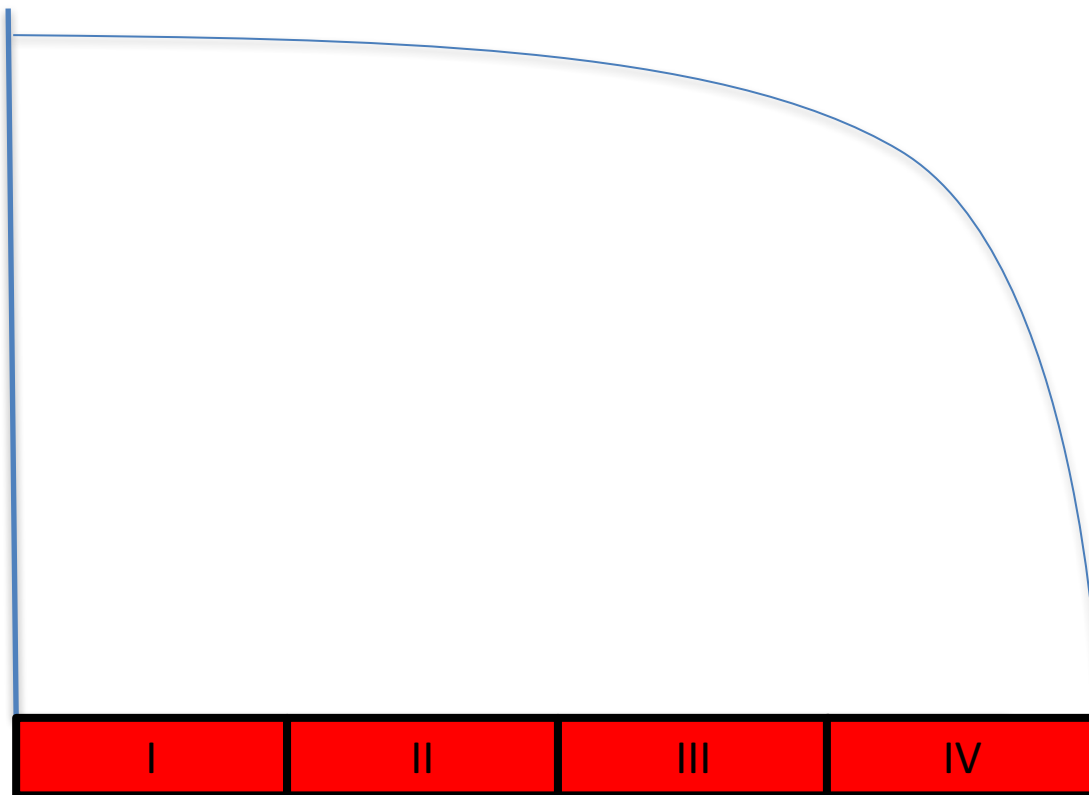


# Classical Haemorrhagic Shock



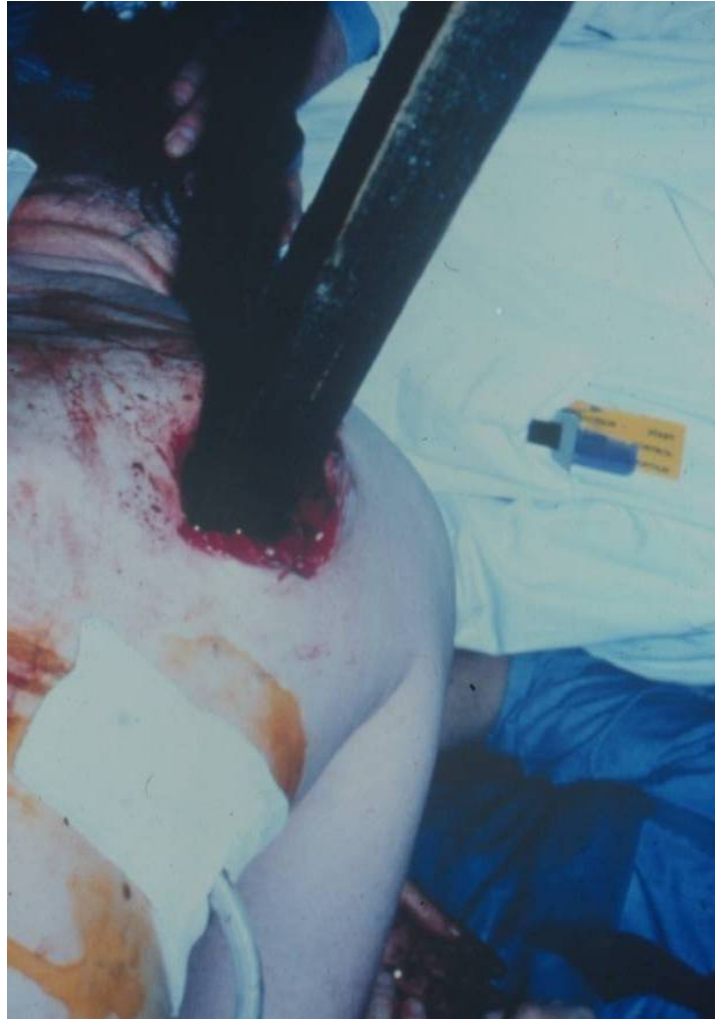Grade of Shock

# Reality



Grade of Shock

So what's the problem?



ATLS manual says:

‘Surgical consultation is mandatory’



And guess what?

What surgeon?

# ‘Emergent’/urgent thoracotomy

Drains in, tube in, fluids in

Non-responder / transient responder

Unable to transfer

- clinical
- environmental

# When to do it?

- Drains Filling
- Actively treating shock
- Failing to oxygenate
- Out of ideas/chest drains!

INDECISION KILLS!

# Why are we in this situation?

- Pulmonary haemorrhage
- Chest wall haemorrhage
- Cardiac laceration
- Massive air leak – lung/tracheobronchial
- Great vessel injury

# Why can't we wait?

- Multiple transfusions
- Acidosis, hyperkalaemia, etc.
- Hypothermia
- Coagulopathy
- Immunosuppression/contamination

# Damage Control

- Apply the principles of DCR
- Prevent patient entering this triad or extricate them
- Ignore anatomy – restore physiology!

# Damage Control Thoracics

- Relieve or exclude tamponade
- Rapidly control haemorrhage
- Control of massive air leak
- Prevent contamination



Early surgical intervention mandatory!

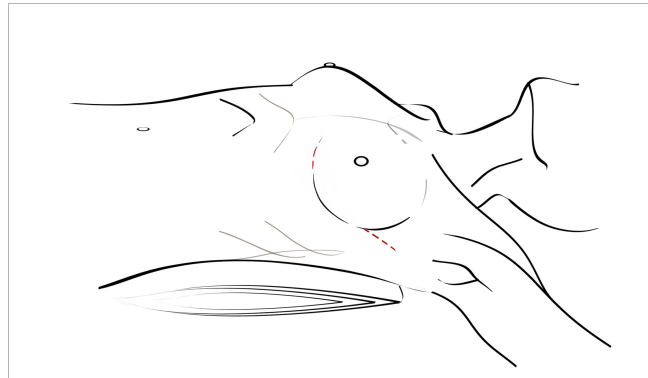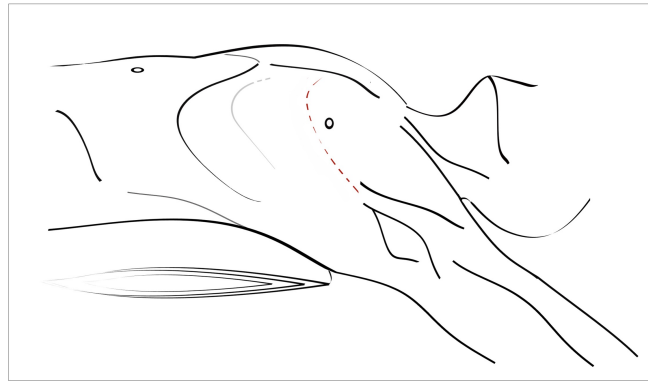
How to do it and what to do?

# Resuscitative Thoracotomy

- Immediate – arrest situation
- Penetrating trauma
- Signs of life at scene
- CPR and ET tube for <15 minutes
- Works for tamponade
  
- For witnessed arrest in Blunt injury <10 minutes

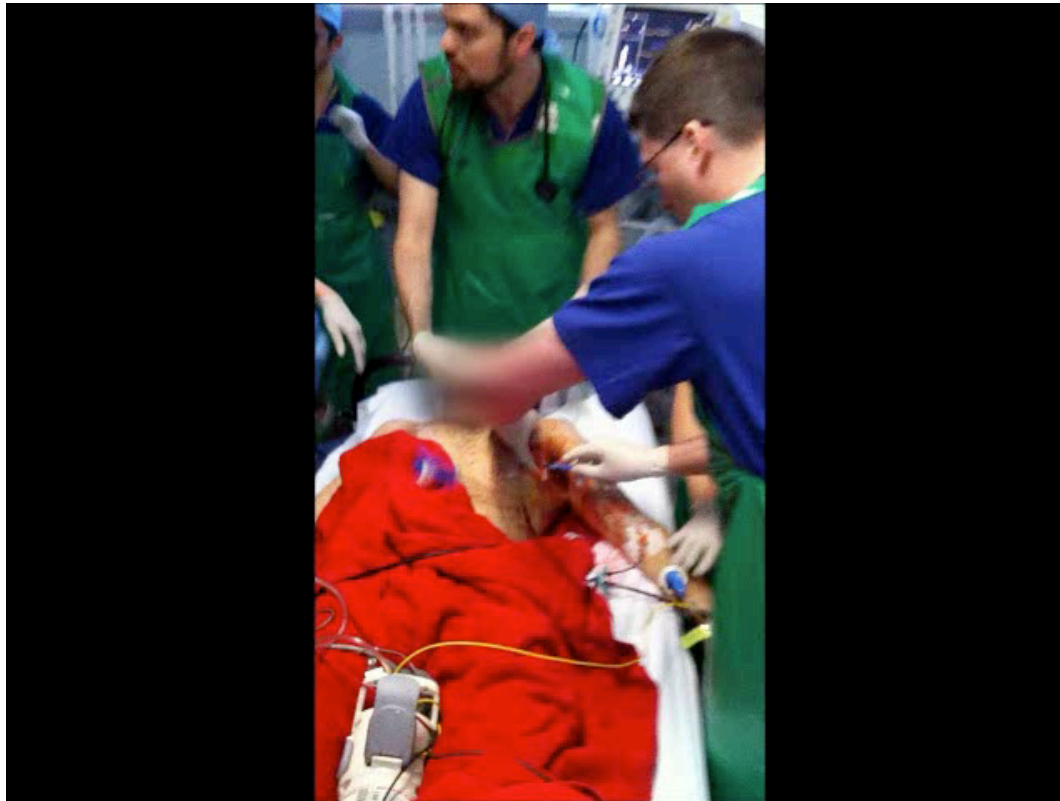
# Resuscitative Thoracotomy

Figure 1. Anterolateral Thoracotomy  
Exposure is improved by placing a bump under the back and the fully extended ipsilateral arm



Time for a willing volunteer!

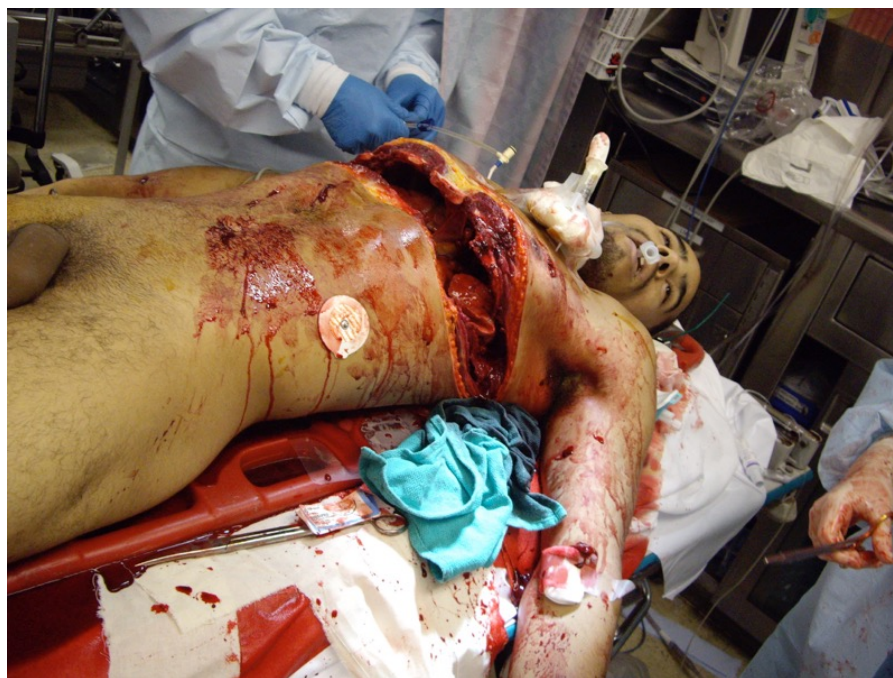No students will be harmed  
(intentionally) during this  
demonstration!



# Resuscitative Thoracotomy for Trauma

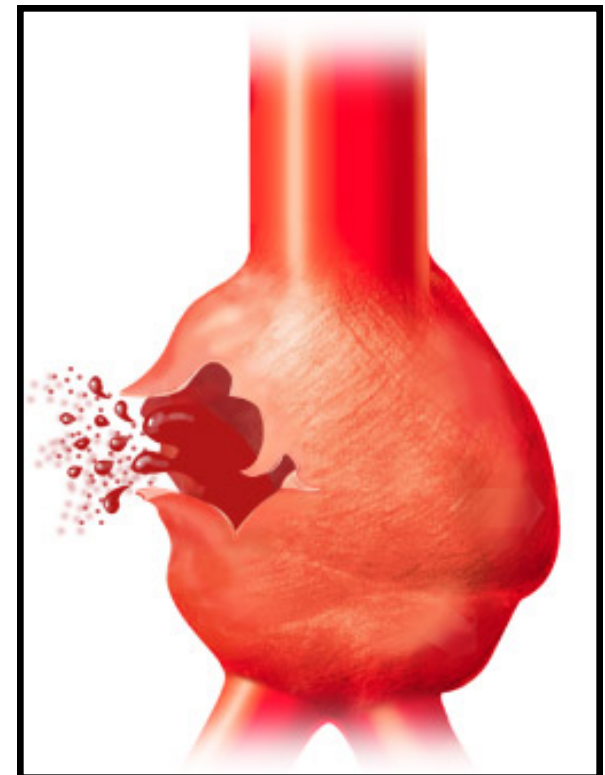
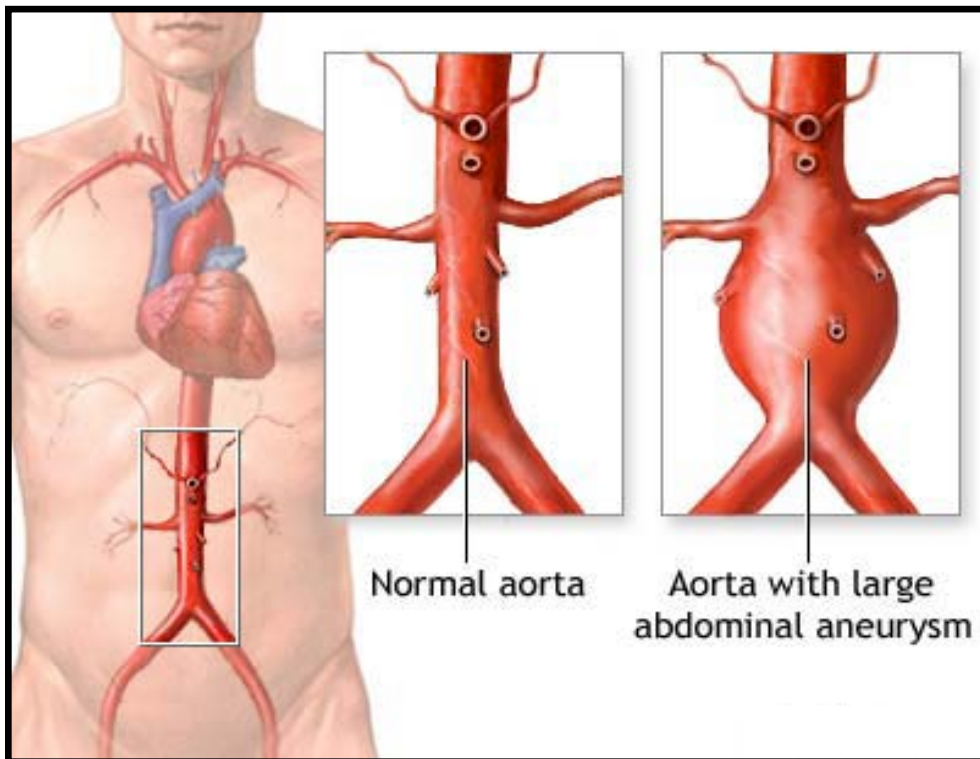
The only hope for a patient in extremis in the ED?

Indications?





# What can we translate from modern approach to ruptured abdominal aortic aneurysms?



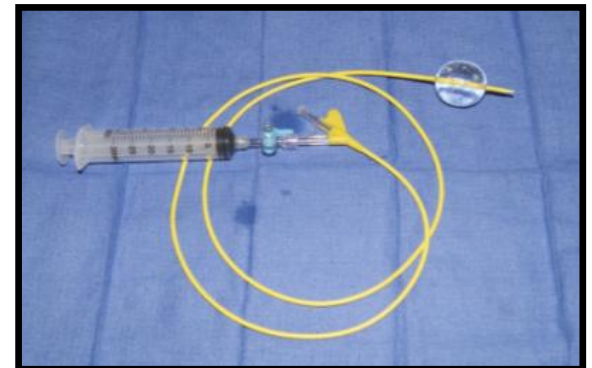
## ORIGINAL ARTICLES

# 10 Years of Emergency Endovascular Aneurysm Repair for Ruptured Abdominal Aortoiliac Aneurysms: Lessons Learned

*Dieter Mayer, MD,\* Thomas Pfammatter, MD,† Zoran Rancic, PhD,\* Lukas Hechelhammer, MD,† Markus Wilhelm, MD,\* Frank J. Veith, MD,‡ and Mario Lachat, MD\**

**Conclusion:** In this 102 patient contemporary series of eEVAR for RAAA, endografting proved to be safe with a 30-day mortality of 13%. Key components of this favorable outcome result were adequate preoperative diagnostic imaging, hypotensive hemostasis, selective transfemoral suprarenal aortic balloon occlusion, predominantly local anesthesia, detection and treatment of ACS, and attention to logistics. Widespread adoption of these treatment components is recommended.

*(Ann Surg 2009;249: 510–515)*



# REBOA in the pre-endovascular era

Low RB et al. *Preliminary report on the use of the Percluder occluding aortic balloon in human beings*. *Annals of emergency medicine*. 1986 Dec;15(12):1466–9.

- 13% survival in 15 trauma patients after REBOA

Gupta BK et al. *The Role of Intra-aortic Balloon Occlusion in Penetrating Abdominal Trauma*. *The Journal of Trauma*. 1989;29(6):861–5.

- 35% survival in 20 trauma patients after REBOA

# Translational Research

## **SURGERY**



Endovascular balloon occlusion of the aorta is superior to resuscitative thoracotomy with aortic clamping in a porcine model of hemorrhagic shock.

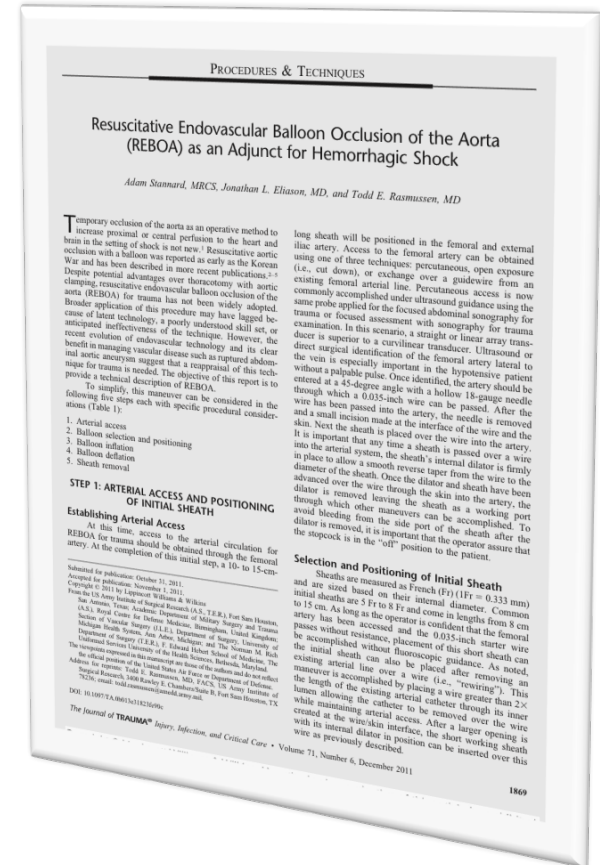
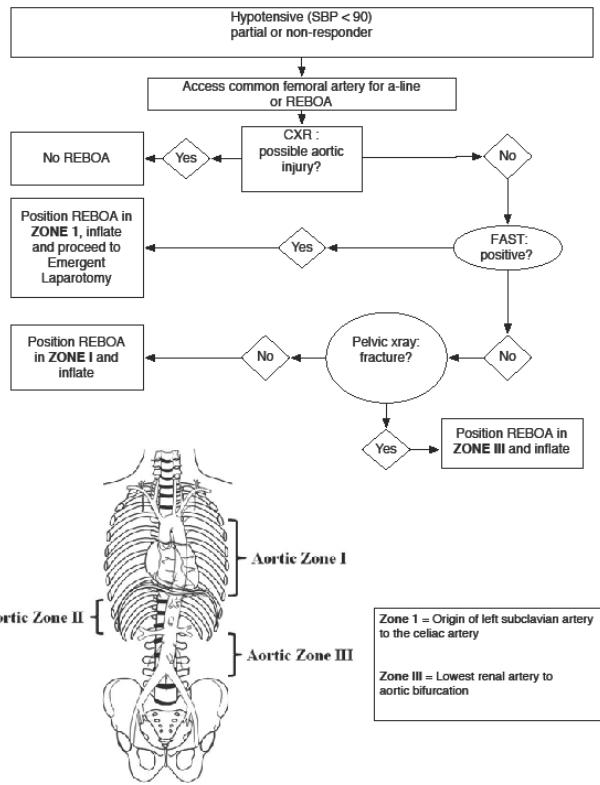
White JM, et al. – *Surgery*. 2011 Sep;150(3):400-9.

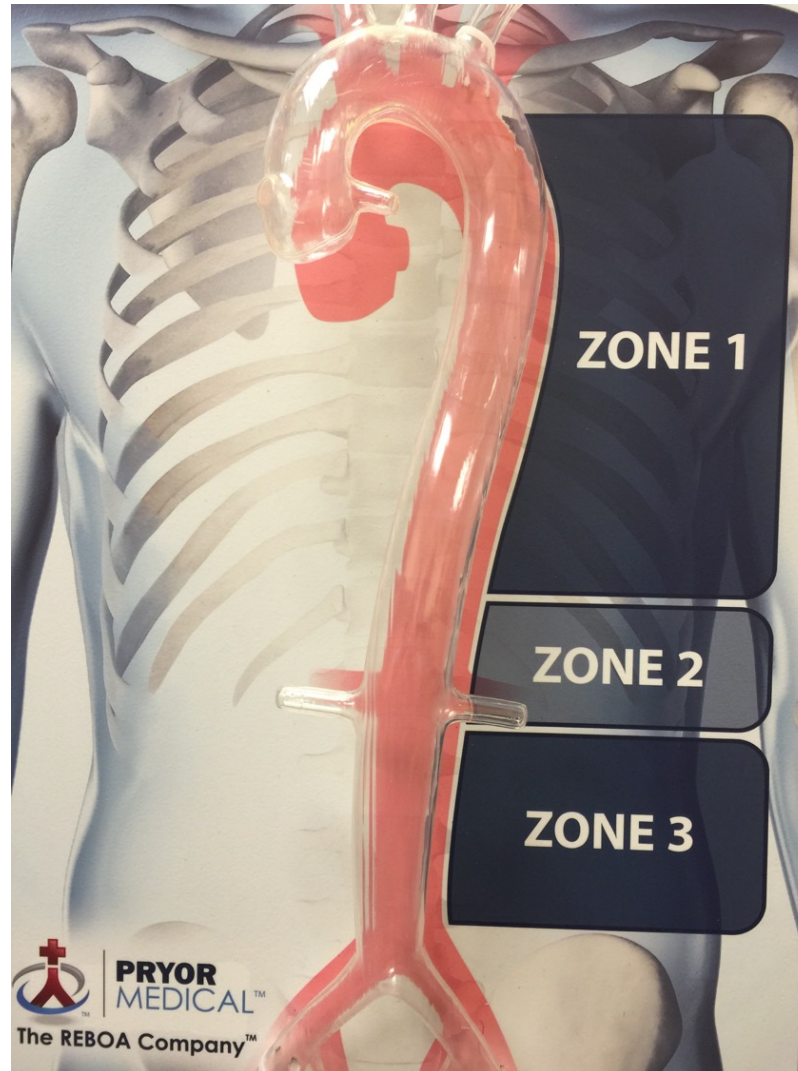

Use of resuscitative endovascular balloon occlusion of the aorta in a highly lethal model of non-compressible torso hemorrhage

Morrison JJ, et al. – *Shock* feb;41(2):130-7.

# Technique for REBOA









# **The AAST Prospective Aortic Occlusion for Resuscitation in Trauma and Acute Care Surgery (AORTA) Registry: Contemporary utilization and outcomes of aortic occlusion and REBOA**

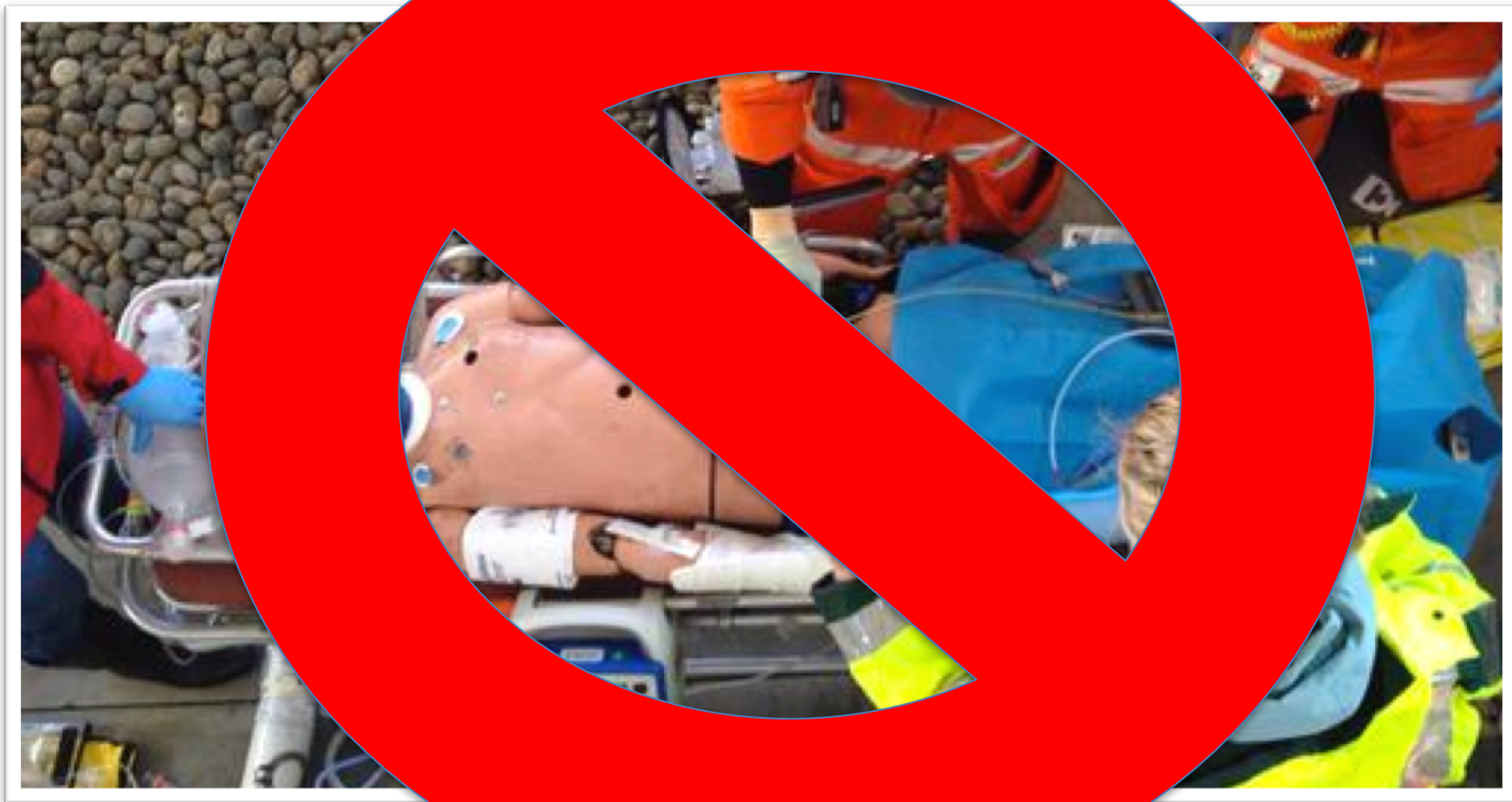
Joseph J. DuBose, MD; Tom Scalea, MD; Megan Brenner, MD; Dimitra Skiada, MD; Kenji Inaba, MD; Jeremy Cannon, MD, Laura Moore, MD; John Holcomb, MD; David Turay, MD; Xian Luo-Owen, MD, PhD; Andrew Kirkpatrick, MD; James Xiao, MD; David Skarupa, MD; Nathaniel Poulin, MD and the *AAST AORTA Study Group*

# Conclusions

- Good outcomes can be achieved after AO
  - 21.1% overall survival; 9.5% ED AO
  - Good neurologic outcomes
- REBOA may represent a viable alternative to Open AO techniques
- **AAST 2017 Update Pending!!!**



# REBO...ide



# REBOA 2017

- Lower profile devices
  - Minimize device-related complications
  - Facilitate full percutaneous access
  - Decrease threshold to utilize
  - Prophylactic placement
- Device capabilities
  - Arterial monitoring port
  - Infusion capabilities?
  - Proximal arterial offloading?

# REBOA 2017: The ER-REBOA Catheter

- FDA-approved
- 7 French
- Arterial Pressure Monitoring
  - Prophylactic
- No Guide wire
- No Fluoroscopy



# How much air?

- Inflation volume:
- “5 or 8 - don’t overinflate” (5 or 8 cc’s)

# How deep?

- Zone 1 insertion depth = 46 cm
- Zone 3 insertion depth = 27 cm

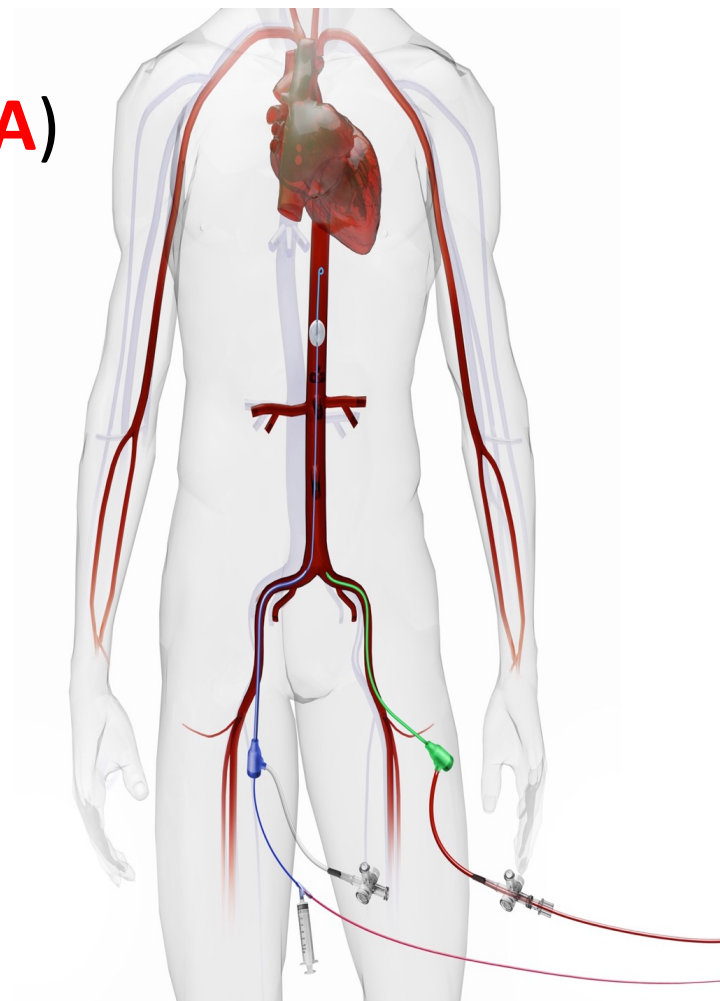
# 6 Steps of REBOA - MEFIIS

- Measure – measure distance
- Evacuate – evacuate the balloon
- Flush – flush the arterial line
- Insert – insert the catheter
- Inflate – inflate the balloon
- Secure – secure the catheter

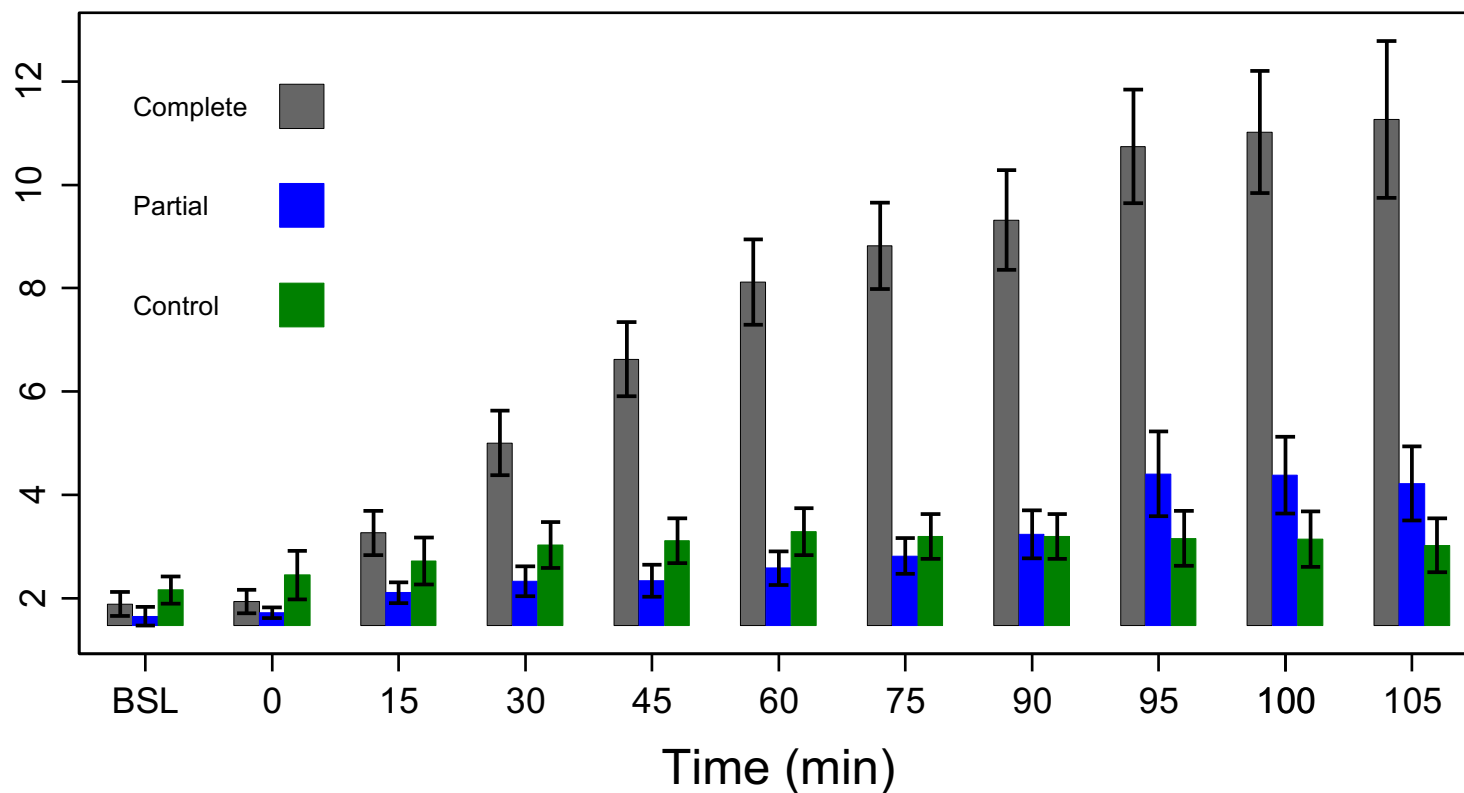
## The Next Generation

### Early Partial REBOA (**P-REBOA**)

- **Preservation perfusion to brain / heart**
- **Avoidance of overpressure**
  - Heart Failure
  - Worsening of TBI
- **Initial total occlusion**
  - Permits resuscitation initiation
  - Clot formation
- **Partial balloon occlusion**
  - Minimizes total ischemic time
  - Mitigates re-perfusion injury risk
  - Extends duration of intervention when needed



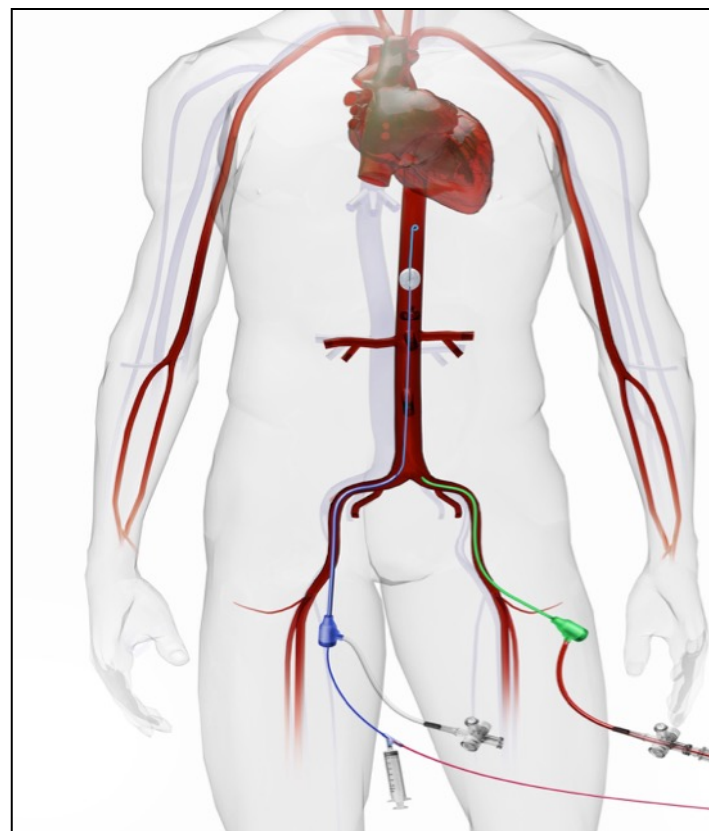
# Metabolic Burden Over Time





# P-REBOA: Clinical Application

1. Approximately 10-20 minutes of complete aortic balloon occlusion
2. Establish distal arterial pressure monitor
3. Deflate balloon until pulsatile distal waveform achieved
4. Stepwise balloon insufflation with pressure monitoring  
Avoid rapid increased in distal pressure; monitor proximally
5. Re-occlude if proximal pressure does not tolerate



Partial Resuscitative Balloon Occlusion of the AORTA (P-REBOA): Clinical Technique and Rationale

M. Austin Johnson, MD, PhD<sup>1</sup>, Lucas P. Neff, MD,<sup>2,3,4</sup> Timothy K. Williams, MD<sup>5</sup>, Joseph J. DuBose, MD<sup>2,3,4,5</sup>; and *The EVAC Study Group*

**Affiliations:**

<sup>1</sup>Department of Emergency Medicine, University of California Davis Medical Center, 2315 Stockton Blvd, Sacramento, CA 95917

<sup>2</sup>Department of General Surgery, David Grant USAF Medical Center, Travis Air Force Base,

<sup>3</sup>UC Davis Medical Center, Sacramento, California 94535

<sup>4</sup>Department of Surgery, Uniformed Services University of the Health Sciences, 4301 Jones Bridge Road, Bethesda, Maryland 20814

<sup>5</sup>Department of Vascular and Endovascular Surgery, David Grant USAF Medical Center, Travis Air Force Base, California 94533



• “How I Do it” Youtube:

- [Part 1 : https://www.youtube.com/watch?v=-U7MkU3eA7E](https://www.youtube.com/watch?v=-U7MkU3eA7E)
- [Part 2 : https://www.youtube.com/watch?v=DZ5LCeT7PBk](https://www.youtube.com/watch?v=DZ5LCeT7PBk)

# IMPORTANT

REBOA is a systemic technique  
not an individual

# Questions?

[manskhan@doctors.org.uk](mailto:manskhan@doctors.org.uk)